

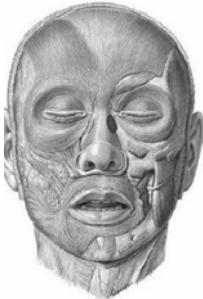
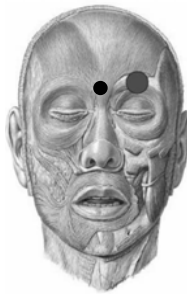

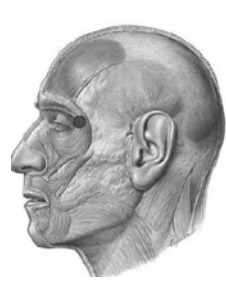





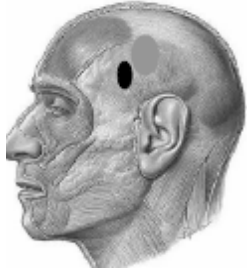








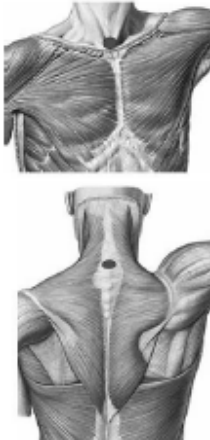





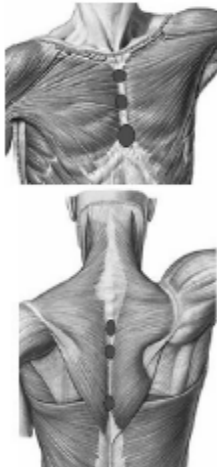











	AN	IR	ME	RE	ER	LA
disor ders	Eye hurt, disturbance to look downwards	Cephalalgia, strabismus	Eye diseases & Rhinoconjunctivitis	Rhinoconjunctivitis, stye, chalazion, sinusitis	Migraine, ophthalmic disorders	Ophthalmic neuralgia
CP 1						
CC	Inferior margin of the orbital fossa, fascia bulbi or tenon's capsule	On the inferior oblique muscle, lateral extremity of the eyebrow	Over the rectus internal muscle, against the nasal septum, under the conjunctiva	In the fascia bulbi or tenon's capsule, medial third of the eyebrow, Over Internal border of eyebrow	Above the external tip of the eyebrow, close to the frontal parietal suture, over the arch of the eyebrow & over the superior oblique muscle of eye	Over lateral canthus of the eye, tenon's capsule at the level of the conjunctive or under it
Patient position	Supine	Supine, head slightly rotated	Supine	Supine	Supine	Supine- Head slightly rotated
Physio' position	Same side	Same side or behind the head	Same side	Same side or behind	Same side	Same side or behind
pressure	light	light	light	light	light	light




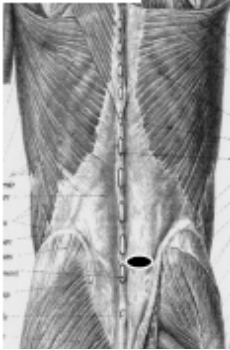


	AN	IR	ME	RE	ER	LA
disorders	Paresis of upper lip, excessive overflow of saliva	Tinnitus, odontalgia, fascial paralysis	Ptyalism, inflammation of the floor of the mouth, dry mouth, cramps in the floor of the mouth	Sinusitis, front-occipital headache	Neuralgia, temporal headache, tinnitus, hearing loss, hyperesthesia of the scalp	Toothache, eyelid spasms, hemicranias, trigeminal neuralgia
CP 2						
CC	On top of zygomaticus m., lateral to the nostril, immediately below AN-CP 1	On the lateral pterygoid muscle, between mandibular condyle & the tragus	Over the raphe of the mylohyoid muscle beneath the mandibula, under the chin	Over the frontal muscles, approximately on the hairline, on the same line of RE-CP1	over the superior auricularis m. Above the helix of the ear	At the center of the temporalis m. ask for strong bite.
Patient position	Supine	Supine, head slightly rotated	Supine	Supine	Supine, head extrarotated	Supine, head extrerotated
Physio' position	Same side	Same side or behind the head	Lying on side	Behind	Same side or behind	Same side or behind
pressure	light	light	light	light	light	light



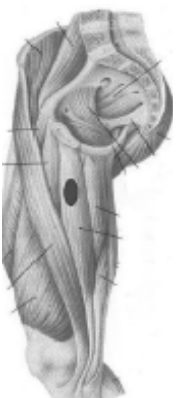



	AN	IR	ME	RE	ER	LA
disorders	TMJ dysfunction	Tinnitus, odontalgia, mumps	Headache daze, head feels heavy, vertigo	Nucal pain, vertigo, headache	Headache, pain in the nuchal area	Pain & neuralgia in the TMJ, deviation of the mandible
CP 3						
CC	Below inf. border of the body of the mandible, on the digastrics superior muscle	Below the tragus, in the dimple created by the opening of the mouth, in the sulcus behind the mandible	Over the occipital insertion of ligament nuchae below the occipital protuberance	Where the erector spinae insert on the occiput on the epicranial fascia at the level of occipital protuberance	Over the posterior auricularis muscle above & behind the mastoid notch	On the muscle belly of masseter
Patient position	Supine, head rotated & extended	Supine, head slightly rotated and mouth slightly open	Seated, forehead resting on hands	Sitting with head resting on hands	Sitting with head resting on hands	Supine or sidelyning
Physio' position	Same side	Same side	Same side	Same side and behind	Same side	Same side
pressure	Light-medium	light	Light-medium	Medium	medium	Light-medium




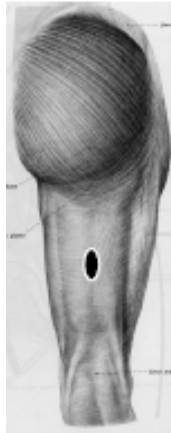


	AN	IR	ME	RE	ER	LA
disorders	Neck pain	Neckpain, vertigo, sternoclavicular erthrititis, dysphonia	Ant: pharyngitis, esophagitis, hiccups, gastric spasm Ret: cervicobrachial pain, general fatigue, cervical disc herniation	Neck pain, dislocated vertebrae	Cervical pain, spinal disc herniation, vertebral subluxation	Cervical pain, arthritis, migraine, pulsating temples, reduction of the intervertebral spaces
CL						
CC	Ant. fibers of the SCM m. at the level of the thyroid cartilage	On the scalenus anterior muscle, between 2 heads of the SCM muscle	AN- In the supra sternal notch' median raphe of the cervical anterior fascia RE- over the interspinous ligament at the level of C7-T1	Under the trapezius muscle, the therapist penetrates laterally to the sixth cervical vertebrae over the erector spinae fascia	Over splenius m. at the level of the transverse process of C2,3	Over lateral border of SCM m, at the level of thyroid cartilage.
Patient position	Supine	Supine, head slightly rotated	AN-Supine RE- Sitting-forehead on hands	Sitting with head resting on hands	Supine Head slightly extrarotated	Supine- Head extrarotated
Physio' position	Same side	Same side	Behind the patient	Same side	Same side, perpendicular to the patient	Same side
pressure	Light-medium	Light-medium	Light-medium	medium	Light-medium	light-medium







	AN	IR	ME	RE	ER	LA
disorders	Sense of oppression in the anterior chest, anxiety	Intercostals pain	Cardiac & precordial pain	Back pain, unilateral scoliosis, arthrosis, chest tightness	Back pain, scapular pain, cervicothoracic pain	Dorsal back pain, intercostals neuralgia, inspiratory difficulty
TH						
CC	Above the rectus abdominis muscle, between inferior costal margin & pectoralis major	Over the 5th/6th intercostal space, on the midclavicular line, below the nipple, to the costal insertion of the pectoralis major	AN: median raphe over the sternum 1) manubrium 2) between the nipples 3) over the xyphoid process RE- infraspinous & supraspinous ligaments 1) T3-4 2) T4-5 3) T7-9	Over the mass of the erector spinae at the T4-T5 level	Medially to the scapula, laterally to erector spinae, above the serratus pos.-sup. At the level of the scapular spine	Over iliocostalis m., in the sulcus between the descending fibers of trapezius & latissimus dorsi, near the inferior angle of the scapula
Patient position	Supine	Supine	AN- Supine RE- Prone	Prone, arm int. rotated along his side	Prone, head rotated to opposite side	Prone, arm abducted, forearm out of the table
Physio' position	Same side	Same side	Beside the patient	Same side or cranial	Behind, cranially	Same side
pressure	medium	Light-medium	light	medium	medium	medium






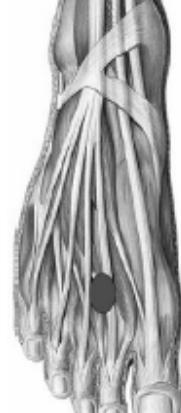
	AN	IR	ME	RE	ER	LA
disorders	LBP, colitis, constipation	Abdominal distension, pain in the hypochondrium, inguinal hernia, groin pain	Ant: chronic dysfunction of the digestive system RE: LBP	Lumbago, LBP, spinal disc herniation	LBP, hypochondrium pain, pain belt	LBP, lumbar arthritis, little intervertebral disc spaces
LU						
CC	Over the Rectus Abd. Muscle, lateral to the umbilicus	On the apex of the 11 th rib, over the oblique m. Anterior to the mid axillary line, against the rib	AN-On linea alba 1) below xyphoid 2) 1/2 way between 3) above umbilicus RE- lig - L1-L5	Over the mass of the erector spinae at the level of L1-2	Over the origin of serratus pos.-Inf on the 12 th rib	Over Quadratus lumborum m. laterally to the transverse process of L2-3
Patient position	Supine	Side-lying or supine	AN-Supine RE- Prone	Prone	Side-lying Or prone	Side-lying
Physio' position	Same side	Same side, sitting on the table in front of the patient	In front of the patient	Same side, turned towards the patient	Behind the patient	Behind the patient
pressure	medium	medium	medium	Medium-strong	medium	medium

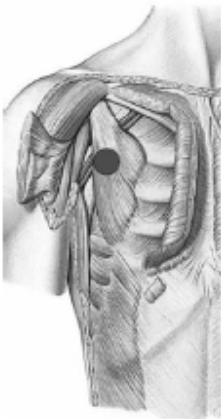




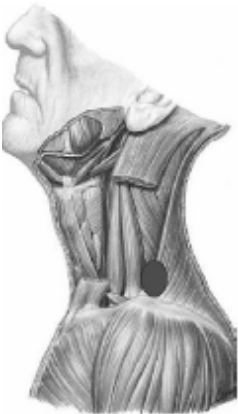
	AN	IR	ME	RE	ER	LA
disorders	Heaviness in the iliac fossa, sacroilitis	Coxalgia, LBP, inginal hernia	Ant: chronic diseases of the urinary & genital apparatus RE: coccydynia, outcomes of trauma to the coccyx, deviations	Sciatic pain, disc herniation, sacroilitis	Coxalgia, neuralgia of the lower limb	LBP with radiation along lower limb
PV						
CC	Medially to iliac crest, on the iliacus muscle	Over the glut mini. M. , in the fossa between greater trochanter and iliac crest. behind the TFL m.	Ant: over the linea alba: 1) below umbilicus 2) halfway between umbilicus & pubic bone 3) over symphysis pubis RE: over the raphe of the pubococcygeus fascia between the sacrum & the coccygeus	Over origin of quadrates lumborum from the iliac crest, over iliolumbar ligament at the level of L4, out and above PSIS	Over the Glut Med m. just below the highest point of the iliac crest	over the glut max at the level of 4 th sacral foramina, 1/2 way the line between PSIS & greater trochanter
Patient position	Supine	Side-lying	AN-Supine RE- Prone	Prone	Side-lying	Side-lying
Physio' position	Same side, turned towards the patient's feet	Sitting behind the patient	Beside the patient	Same side, turned towards the patient's feet	Behind the patient	Behind the patient
pressure	medium	Medium-strong	medium	Medium-strong	Medium-strong	Medium-strong







	AN	IR	ME	RE	ER	LA
disorders	Pain in the hip, osteitis pubis	Femoral canal congestion, athletic pubalgia	Coxalgia, athletic pubalgia "osteitis pubis", adductor tendinitis	Sciatic pain, iscial bursitis, insertional upper hamstring tendinitis	Sciatic pain, piriformis syndrome, arthritis	"meralgia paraesthetica", cramps of the TFL muscle
CX						
CC	Beneath inguinal lig., medial to Sartorius sheath, against the iliopsoas fascia	Against the inferior angle of the scarp's triangle	on the proximal part of the gracilis muscle	On the Glut Max m. at the level of sacrotuberous lig. Between ischial tub. And PSIS-closer to ischial tub.	1/2 way between the greater trochanter & sacrum over piriformis m.	Over muscle belly of tensor fascia lata
Patient position	Supine	Supine /Side-lying on the painful side	Side-lying on the painful side hip flexed or extended	Lying on opposite side, legs overlapped	Side-lying, hip flexed, uppermost knee resting on the table	Sidelying, overlapping legs
Physio' position	Same side	In front of patient	In front or behind the patient	Same side	Behind the patient	In front of patient
pressure	medium	medium	Medium-strong	Medium-strong	Medium-strong	Medium-strong







	AN	IR	ME	RE	ER	LA
disorders	Patella's tendinitis, bursitis, CMP	Goose foot tendonitis, degenerative medial meniscus tear	Goose foot tendonitis, medial knee instability, panniculitis, cellulitis	Biceps femuris tendinitis, Baker's cyst	Biceps femuris tendonitis, ITB syndrome, lateral meniscus tear	Femoropatellar laxity, injury to the LCL
GE						
CC	over vastus intermedius, lateral to the rectus femoris, midway the thigh.	Over the muscle belly of Vastus medialis, anteriorly to the Sartorius muscle	Over the Gracilis m. , middle 1/3 of the thigh, posteriorly to sartorius	medially to the biceps femoris , 1/2 way the pos. part of the thigh	where short head originates from the lateral septum, approximately between the middle third & the distal one	Over the iliotibial tract, near the origin of short head of biceps femoris, halfway the thigh
Patient position	Supine	Side-lying on the painful side	Side-lying on the painful side	Prone	Prone, knee semi flexed	Prone-hip semi flexed or Side lying
Physio' position	Same side	In front of patient	Behind the patient	Same side caudally	Same side	Same side
pressure	medium	medium	medium	Medium-strong	Medium-strong	Medium-strong







	AN	IR	ME	RE	ER	LA
disorders	Tendinitis of tibialis anterior or extensor digitorum	Talar spur, algodystrophy	Tendinitis, inflamed heel, tarsal tunnel syndrome, plantar fasciitis	Achilles tendinitis/tenosynovitis, calcaneal spur	Peroneal tendonitis, inflamed heel, ankle sprain	Tendonitis, traumatic injury of ligaments, chronic ankle sprains
TA						
CC	Over Tibialis Ant. M. half way of leg shin	where the Tibialis pos. inserts in the medial part of the deep transverse fascia, midway the leg	Over the triceps surae where the soleus & gastro. Medialis unite	Over myotendinous passage of the lateral gastro.	Behind fibula over peroneal m. 1/2 on lower leg	Over extensor digitorum longus and peroneus tertius, midway the leg, over or anterior to fibula
Patient position	Supine	Side-lying on the painful side	Side-lying on the painful side	Prone	Prone, knee semi flexed	Prone, Side leg
Physio' position	Same side	In front of the patient	Behind the patient	Same side	Same side	Same side
pressure	medium	medium	Medium-strong	Medium-strong	Medium-strong	Medium-strong


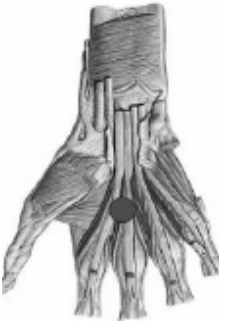




	AN	IR	ME	RE	ER	LA
paraesthesia	Toe 1	Toe 1	Toe 2,3,4	Toe 5	5Toe	Toe 2,3,4
disorders	Parasthesia to the first toe, tendinitis of extensor hallucis, ingrown toe nails	Hallux valgus, tendonitis, arthritis	Pes planus, pes cavus, plantar fasciitis, cramps	Metatarsal arthritis, contracture of abductor digiti minimi	Callus formation, hammer toes, cramps toes	Morton's neuroma, deformation of the toes, callosity under the metatarsal heads
Pe						
CC	between the 1 and 2 metatarsal bone	Over the anterior part of the abductor hallucis m., in the middle of the longitudinal plantar arch below the navicula bone	Over the insertion of Tibialis pos. against the heel	Over the abductor dig. Minimi, behind and sometimes ahead the base of fifth metatarsal bone	In front of the lateral malleolus, Over the extensor digitorum brevis	Over the 2,3 dorsal interossei m.
Patient position	Supine, knee flexed with foot resting on table	Side-lying on the painful side	Side-lying on the painful side	Prone, side leg	Supine, lower limb flexed with the plant of foot on the table	Supine, foot resting on the table
Physio' position	Same side	Standing on the same side	Behind the patient	Same side	Same side	Same side

pressure	medium	Medium	Medium-strong	medium	medium	Light-medium
	AN	IR	ME	RE	ER	LA
disorders	Trauma or sprain in ACJ, pectoralis minor syndrome, brachial plexus irritation	Periarthritis, acromioclavicular dislocation and clavicle fractures	Long thoracic nerve paresis, rib pain, precordial pain	Neck pain, upper limbs weakness and paresthesia	Cervicobrachial syndrome	Cervicobrachial syndrome
SC						
CC	Beneath coracoids process, in the groove between deltoid and pectoralis over the belly of pectoralis minor and clavi coraco axillary fascia	Beneath the middle 3rd of the clavicle, on the muscle belly of subclavius	over Serratus ant. m., 6 intercostal spaces, below the axilla	On the rhomboids muscles at T2 level	Over the levator scapula m. on the superior border of trapezius medially to the supraspinatus fossa	Over scalenus medius, between upper trapezius & SCM
Patient position	Supine or seated	Supine or seated	Supine, arm abducted or side lying arm elevated	Sitting with head resting on contra lateral hand	Sitting with head resting on contralateral hand	Sitting
Physio' position	Same side	Same side, behind the patient	Same side	Behind the patient	Behind	behind
pressure	medium	medium	Light-medium	medium	medium	medium

	AN	IR	ME	RE	ER	LA
disord ers	Periarthritis, tendinitis of LHB	Periarthritis, tendinitis of the pectoralis major	Periarthritis, brachialgia	Axillary adenopathy, periarthritis	Periarthritis, arm pain	Periarthritis, pain in the arm, tendinitis of LHB
HU						
CC	Medially to the long head of biceps, over the ant. deltoid	Beneath the pectoralis major tendon, in the humeral insertion of coracoclavicular fascia	Behind the coracobrachialis m. Over medial intermuscular septum	In the sulcus among the latissimus dorsi, long head of triceps, teres major and minor	Just behind the rotator cuff, Over pos. fibers of deltoid muscle & infraspinatus	Over the lat. Fibers of Deltoid m. laterally to LHB
Patient position	Supine in anatomical position or seated	Supine- arm abducted & externally rotated	Supine, upper limb abducted & extrarotated, elbow is flexed	Prone, upper limb abducted & intrarotated, forearm out of bed	Side lying	Side lying or seated or supine
Physio' position	Same side	Same side, holding the wrist	Same side	Same side	Same side	Same side
pressure	medium	medium	Light-medium	medium	medium	medium

	AN	IR	ME	RE	ER	LA
disorders	Epicondylitis, cramps of the biceps	Medial epicondylitis, median nerve neuropathy	Medial epicondylitis, numbness of the arm & hand, tremors limb	Olecranon bursitis, post traumatic stiff	epicondylitis	Epicondylitis, tendonitis, elbow rigidity, paraesthesia
CU						
CC	Over the biceps m. , at the level of the distal tendon of deltoid	Over the pronator teres m. slightly below the elbow crease	Slightly ahead at the medial intermuscular septum, over originated the flexor carpi ulnaris	Over muscle belly of the lateral head of triceps, at the level of deltoid's distal tendons	Over the origin of supinator muscle from the lateral intermuscular septum	at level of radial head & in the sulcus between Extensor Radialis Longus & brachioradialis
Patient position	Supine in anatomical position	Supine	Side lying, flexed shoulder	Prone arm Abd	Prone , arm sidelong	Prone , hand above the head
Physio' position	Same side	Same side	Same side	Same side	Same side	Same side
pressure	medium	medium	Light-medium	medium	medium	medium

	AN	IR	ME	RE	ER	LA
disorders	Tendinitis of flexor carpi radialis, writer's cramp	Muscle contracture, entrapment of the median nerve, tendinitis, CTS	Spasm of the hand, hot sensation on the hypothenar eminence	Tendinitis of extensor carpi ulnaris	Extensor tendonitis, cysts	Dequervain's syndrome, carpal rheumatism
CA						
CC	Over the antebrachial fascia, between the proximal and middle third of the forearm, in the sulcus between the brachioradialis and flexor carpi radialis	On the proximal part of pronator quadrates, between tendons of Palmaris longus and flexor radialis carpi muscles	Over the flexor carpi ulnaris, in the passage between middle & distal 3 rd of the forearm	Over the distal 1/3 of extensor carpi ulnaris m.	Over m. belly of extensor digitorum & extensor pollicis longus	Over the muscle bellies of extensor carpi radialis longus+brevis
Patient position	Supine or seated	Supine/seated	Prone, upper limb intra rotated pulm up	Prone, arm sidelong, palm down	Prone, arm near the head, palm down	Prone, arm on the table above the head
Physio' position	Same side	Same side	Same side	Same side	Same side	Same side
pressure	medium	Medium-strong	medium	medium	medium	medium

	AN	IR	ME	RE	ER	LA
paraesthesia	Fin 1	Fin 3	Fin 5	Fin 5	Fin 4	Fin 2
disorders	Writer's cramp	CTS, Dupuytren's contracture	Dupuytren's contracture, paresis of palmar interossei	OA of the fifth finger, poly-articular syn.	Interphalangeal osteoarthritis	Painful paraesthesia of MCP joint, ROM limitation of the 2 nd finger
DI						
CC	Over the thenar eminence, half way of first metacarpal bone	On the palmar aponeurosis, between 2 nd / 3 rd or 4 th metacarpal bone	midway the hypothenar eminence over the Palmaris brevis & flexor digiti minimi	Over abductor digiti minimi, at the base of the 5 metacarpal bone	Over the dorsum of the hand, between 3 rd / 4 th / 5 th metacarpal bone	Over 1 st dorsal interosseous m., on the fascia that extends between Abd Poll and the tendons of the other fingers.
Patient position	Supine or seated	Supine/seated	Prone, upper limb intra rotated, palm up	Prone, arm sidelong with the anatomical snuffbox against the table	Prone, upper limb above the head/ Sitting	Prone, hand above the head
Physio' position	Same side	Same side	Same side	Same side, hold the patient's hand	Same side	Same side, hold the patient hand
pressure	Light-medium	medium	Light-medium	Light-medium	light	Light-medium

